

# Exploring the Genetic Basis of 3MC Syndrome: Findings in 12 Further Families

Jill Urquhart,<sup>1,2</sup> Rebecca Roberts,<sup>3</sup> Deepthi de Silva,<sup>4</sup> Stavit Shalev,<sup>5</sup> Elena Chervinsky,<sup>5</sup> Sheela Nampoothiri,<sup>6</sup> Yves Sznajer,<sup>7</sup> Nicole Revencu,<sup>7</sup> Romesh Gunasekera,<sup>8</sup> Mohnish Suri,<sup>9</sup> Jamie Ellingford,<sup>1,2</sup> Simon Williams,<sup>2</sup> Sanjeev Bhaskar,<sup>2</sup> and Jill Clayton-Smith<sup>2\*</sup>

<sup>1</sup>Faculty of Medical and Human Sciences, Institute of Human Development, Manchester Centre for Genomic Medicine, University of Manchester, Manchester Academic Health Science Centre (MAHSC), Manchester, United Kingdom

<sup>2</sup>Manchester Centre for Genomic Medicine, Central Manchester University Hospitals NHS Foundation Trust, MAHSC, Manchester, United Kingdom

<sup>3</sup>Manchester Medical School, University of Manchester, Manchester, United Kingdom

<sup>4</sup>Faculty of Medicine, Department of Physiology, University of Kelaniya, Ragama, Sri Lanka

<sup>5</sup>Genetic Institute, Ha'Emek Medical Center, Afula, Israel

<sup>6</sup>Amrita Institute of Medical Sciences, Kochi, Kerala, India

<sup>7</sup>Cliniques Universitaires Saint-Luc, Centre for Human Genetics, Brussels, Belgium

<sup>8</sup>Department of Plastic Surgery, Lady Ridgeway Hospital, Colombo, Sri Lanka

<sup>9</sup>Nottingham Clinical Genetics Service, Nottingham University Hospitals NHS Trust, City Hospital Campus, Nottingham, United Kingdom

Manuscript Received: 18 March 2015; Manuscript Accepted: 22 December 2015

The 3MC syndromes are a group of rare autosomal recessive disorders where the main clinical features are cleft lip and palate, hypertelorism, highly arched eyebrows, caudal appendage, post-natal growth deficiency, and genitourinary tract anomalies. Ophthalmological abnormalities, most notably anterior chamber defects may also be seen. We describe the clinical and molecular findings in 13 individuals with suspected 3MC syndrome from 12 previously unreported families. The exclusion of the *MASPI* and *COLEC11* loci in two individuals from different consanguineous families and the absence of mutations in four further individuals sequenced for both genes raises the possibility that there is further genetic heterogeneity of 3MC syndrome. © 2016 Wiley Periodicals, Inc.

**Key words:** 3MC syndrome; *MASPI*; *COLEC11*; Malpuech syndrome; Carnevale syndrome; Michels syndrome; Mingarelli syndrome

## INTRODUCTION

The 3MC syndromes [Titomanlio et al., 2005] are a group of rare autosomal recessive disorders in which hypertelorism, ptosis, and high arched eyebrows are associated with orofacial clefting. In addition to clefting and hypertelorism, the 3MC syndromes are particularly characterized by the presence of an unusual caudal cyst or appendage, genitourinary abnormalities and intellectual disability. Some patients have also been reported with skeletal anomalies and hearing loss with vestibular anomalies [Mingarelli et al., 1996; Sirmaci

### How to Cite this Article:

Urquhart J, Roberts R, de Silva D, Shalev S, Chervinsky E, Nampoothiri S, Sznajer Y, Revencu N, Gunasekera R, Suri M, Ellingford J, Williams S, Bhaskar S, Clayton-Smith J. 2016. Exploring the genetic basis of 3MC syndrome: Findings in 12 further families.

Am J Med Genet Part A 170A:1216–1224.

et al., 2010]. This group of conditions was originally described as four separate disorders: Malpuech syndrome, Carnevale syndrome, Michels syndrome, and Mingarelli syndrome [Michels et al., 1978; Malpuech et al., 1983; Carnevale et al., 1989; Mingarelli et al., 1996].

The presence of cleft lip and palate, which is often bilateral, is thought of as a key feature in individuals with Malpuech syndrome

Conflict of interest: none

Grant sponsor: Healing Foundation UK Cleft Cooperative.

\*Correspondence to:

Jill Clayton-Smith, MB, ChB, MD, FRCP, Manchester Centre for Genomic Medicine, Institute of Human Development, University of Manchester, St. Mary's Hospital, Oxford Road, Manchester M13 9WL, United Kingdom.

E-mail: jill.clayton-smith@cmft.nhs.uk

Article first published online in Wiley Online Library

(wileyonlinelibrary.com): 20 January 2016

DOI 10.1002/ajmg.a.37564

[Malpuech et al., 1983] whereas Carnevale syndrome patients were initially ascertained through recognition of their distinctive facial appearance with marked ptosis, hypertelorism, downslanting palpebral fissures and synophrys [Carnevale et al., 1989]. In the patients described by Michels et al. [1978] anterior segment dysgenesis was a prominent feature and in those reported by Mingarelli et al. [1996] skeletal findings including radio-ulnar synostosis were identified as distinctive features along with hearing deficits due to abnormalities of the vestibule and semi-circular canals.

There is considerable overlap between all of the above phenotypes [Titomanlio et al., 2005; Leal et al., 2008], which have similarities in facial appearance, leading to the suggestion that they should all be considered part of the same phenotypic spectrum known as 3MC syndrome. This clinical overlap has since been confirmed by the finding of mutations within the *COLEC11* and *MASPI* genes, which encode proteins within the lectin complement pathway, in individuals with all of these disorders [Sirmaci et al., 2010; Rooryck et al., 2011].

The number of 3MC patients with known mutations in *COLEC11* or *MASPI* reported so far remains small. Sirmaci et al. [2010] reported two families with *MASPI* mutations. Rooryck et al. [2011] reported a further 11 3MC families of which 4 had mutations in *MASPI* (two families had the same mutation) and 7 had *COLEC11* mutations. More recently Atik et al. [2015] reported six patients with *MASPI* mutations. Here we report the clinical findings and results of genetic analysis of a further 13 patients from 12 families who were referred initially with a clinical diagnosis of Malpuech syndrome.

## METHODS

### Ascertainment and Clinical Features

Thirteen individuals with a clinical diagnosis of Malpuech syndrome were ascertained through clinical geneticists as part of a broader, ethically approved research study which aimed to identify the genetic basis of rare autosomal recessive disorders. Ethical approval for this study was obtained from the North Manchester Research Ethics Committee (REC ref: 06/Q1406/52).

Family and medical histories, clinical features, growth parameters, and details of intellectual development were recorded in all cases. Photographs of each patient were reviewed.

### Genetic Studies

DNA was extracted from lymphocytes using standard techniques. Genome-Wide SNP analysis using the Affymetrix Genome-Wide SNP6.0 microarray was carried out in six individuals where there was a family history of consanguinity to enable the identification of areas of homozygosity (individuals 1–4, 8, and 12). Genotypes were generated using the Birdseed v2 algorithm with a confidence threshold of 0.01 within the Affymetrix Genotyping console. Autozygosity analysis was carried out using AutoSNPa (<http://dna.leeds.ac.uk/autosnpa/>) [Carr et al., 2006]. All co-ordinates given are based on hg19.

For Sanger sequencing primers were designed for individual exons and intron boundaries to two isoforms of *COLEC11* (NM\_199235.1 and NM\_024027.3) and all three isoforms of *MASPI* (NM\_001879.5,

NM\_139125.3 and NM\_001031849.2) with Primer3 (<http://frodo.wi.mit.edu/>). PCR was performed on genomic DNA with Abgene ReddyMix PCR Mastermix and sequencing was performed with BigDye terminator cycle sequencer system v3.1 (primer sequences and experimental conditions available on request).

Whole Exome sequencing was carried out using the SureSelect Human All Exon Kit v5 (Agilent, Santa Clara, CA) for the Illumina HiSeq 2500 system (San Diego, CA). Sequence data were mapped to the hg19 reference human genome using the Burrows–Wheeler aligner software (version 0.6.2; <http://bio-bwa.sourceforge.net>). Genome Analysis Tool Kit software (version 2.4.7; <https://www.broadinstitute.org/gatk>) was used for recalibration of base quality score and for indel realignment before using the unified genotyper (<https://www.broadinstitute.org/gatk>) for variant calling. Exonic copy number variation (CNV) was assessed using ExomeDepth software (version 1.1.6; Plagnol et al., 2012).

## RESULTS

### Clinical Details

The clinical features of the 13 study patients are shown in Tables I and II. All had initially been suspected to have Malpuech or 3MC syndrome by their referring clinical geneticist. In 10 individuals the presence of cleft lip and palate had led to this suspected clinical diagnosis. In the remaining patients the diagnosis was based on other features including hypertelorism, ptosis, and an abnormal sacrum with a caudal appendage (8), or sacral pit (2) or other unusual appearance (1). Developmental problems were common to all patients but ranged from mild to severe. In review of the clinical features, and when further follow-up information was obtained, patients 9, 10, 12, and 13 were considered less typical of 3MC syndrome but were included in molecular analysis to explore the breadth of the phenotypic spectrum of this disorder. Photographs of patients 4–7 and 11 are shown in Figure 1.

### SNP Array Analysis

Autozygosity mapping was carried out for individuals 1–4, 8, and 12 who were known to be from consanguineous families using SNP array data. This demonstrated that siblings 1 and 2 were homozygous for the *COLEC11* Locus at 2p25 between markers rs4854277 and rs270837 (769,886–7,786,679). In addition individuals 3 and 4 were homozygous for the *MASPI* Locus at chromosome 3q27. For individual the region was between markers rs2981027 and rs383443 (128,184,416–196,974,318) and for individual 4 the region was between rs4389455 and rs17423976 (184,468,768–189,060,510). Individuals 8 and 12 were not homozygous for either the *MASPI* or the *COLEC11* Loci but demonstrated 23 and 21 other regions of homozygosity greater than 2 Mb, respectively (data not shown). Between these two individuals there was one region of overlap at chr3: 125,875,312–132,543,775.

### Sanger Sequencing Analysis

Based on the results of the autozygosity mapping sequencing of *COLEC11* was carried out for individuals 1 and 2 and sequencing of *MASPI* was carried out for individuals 3 and 4. In addition both

TABLE I. Clinical Findings of the Patients Included in the Current Study Who Have Mutations in Either *COLEC11* or *MASP1* and Summary of Previously Reported Cases

**COLEC11**

**MASP1**

Patient Mutation identified	1	2	3	4	5	6	7	Reported
Gender	M	M	F	F	M	M	F	7F/9M
Origin	Israel	Israel	Israel	Sri Lanka	Sri Lanka	Sri Lanka	India	
Birth weight	3,515 g	Normal for 22w fetus	3,235 g	3,150 g	3,250 g	3,150 g	1,290 g	
Height (%)	Term -1 to 2SD at 14 m	NA	Term -5SD at 2 y	Term -4SD at 4y	Term -3SD at 9y	Term -3SD at 7 y	-2 SD at 7y	
Head circumference (%)	+2 SD at 14 m	NA	-1SD at 2 y	NA	-3SD at birth	-3SD at 4y	-4 SD at 7 y	
Consanguinity	+	+	+	+	-	+	+	11/15 (73%)
Intellectual disability	Mild	NA	Moderate	-	Mild	Mild	Mild	4/13 (30%)
Abnormal skull shape	Dolico-cephaly	-	-	-	Plagio-cephaly	-	Turri-cephaly	3/10 (30%)
Highly arched eyebrows	+	NA	+	+	+	+	+	15/15 (100%)
Telecanthus/hypertelorism	+	+	+	+	+	+	+	13/15 (87%)
Ptosis	+	NA	+	+	+	+	+	15/15 (100%)
Cleft palate/lip	+	+	+	+	+	+	+	8/15 (53%)
Abnormal umbilicus/diastasis	-	-	Umbilical hernia	-	-	Diastasis	-	4/15 (27%)
Genitourinary anomaly	Hypospadias	-	+	-	-	Recti	-	6/15 (40%)
Caudal appendage	+	+	+	+	+	+	Unusual sacrum	11/15 (73%)
Hearing loss	-	NA	+	-	-	+	-	10/14 (71%)
Congenital heart disease	-	-	VSD	-	-	ASD	-	5/14 (36%)
Skeletal anomalies	Subluxed hip	-	-	Radioulnar synostosis	-	PDA	-	2/15 (13%)
Neurological/MRI abnormality	Ethmoidal myelo-meningocele, tethered cord	NA	hydrocephalus	NA	NA	Seizures, Tethered filum	Birth asphyxia	
Other	Pyloric stenosis	Atresia of larynx	Haemangioma on spine, Hypopigmented retina, TOF, Skin tag at xiphisterum,	Neonatal teeth	-	-	Skin tag over xiphisterum	

NA, not available; VSD, ventricular septal defect; ASD, atrial septal defect; PDA, patent ductus arteriosus; TOF, trachea-oesophageal fistula.

**TABLE II. Clinical Findings of the Patients Included in the Current Study Who Do Not Have Mutations in *COLEC11* or *MASP1* and a Comparison of Mutation Positive and Mutation Negative Cases from the Current Study**

Patient	8	9	10	11	12	13	Mutation positive (%)	Mutation negative (%)
Gender	F	M	M	M	M	F		
Origin	Israel	Sri Lanka	Belgium	Belgium	Israel	Sri Lanka		
Birth weight	1,700 g at 36 w	1,700 g term	3,640 g term	2,260 g term	590 g term <sup>a</sup>	NA		
Height (%)	-4 to 5 SD at 10 y	-3 SD at 9 y	-1 SD at birth	-3SD at birth	-6 SD at 17 m	-4SD at 5 y		
Head circumference (%)	-3 to 4 SD at 10 y	NA	-1 SD at birth	-2 SD at birth	-5 SD at 17 m	-4SD at 5 y		
Consanguinity	+	-	-	+	+	-	86	50
Intellectual disability	Mild	Mod/severe absent speech	Severe, absent speech	Mild	Motor delay, Not standing age 17 m	Not walking at 2 y, 4 words		
Abnormal skull shape								
Highly arched eyebrows	±	-	-	-	Brachy-cephaly <sup>+</sup> <sup>+</sup> <sup>b</sup>	-	43	33
Telecanthus/hypertelorism	+	-	+	+	-	+	100	67
Prosis	-	-	-	-	-	+ <sup>c</sup>	100	17
Cleft palate/lip	- <sup>d</sup>	-	+	+	+	+	100	83
Abnormal umbilicus/diastasis	Umbilical hernia	-	Omphalocele	Diastasis recti	Umbilical hernia	-	29	67
Genitourinary anomaly	Hydro-nephrosis hydroureter	Micropenis	Hypospadias, Bilateral VUR	Hypospadias, L. renal agenesis	Hypospadias, inguinal hernia	-	29	83
Caudal appendage	+	+	Deep horizontal dimple	+	-	Sacral pit	100	83
Hearing loss	-	-	-	+	-	-	33	17
Congenital heart disease	VSD	-	Truncus arteriosus, VSD	Fallot's tetralogy	-	ASD	29	66
Skeletal anomalies	Long thorax	-	Clinodactyly Vth finger	13 pairs ribs2/3 syndactyly	-	Radial aplasia	29	66
Neurological/MRI abnormality	NA	ADHD	NA	NA	NA	NA		
Other	Fetal pads	Nasal regurgitation	-	-	-	-		

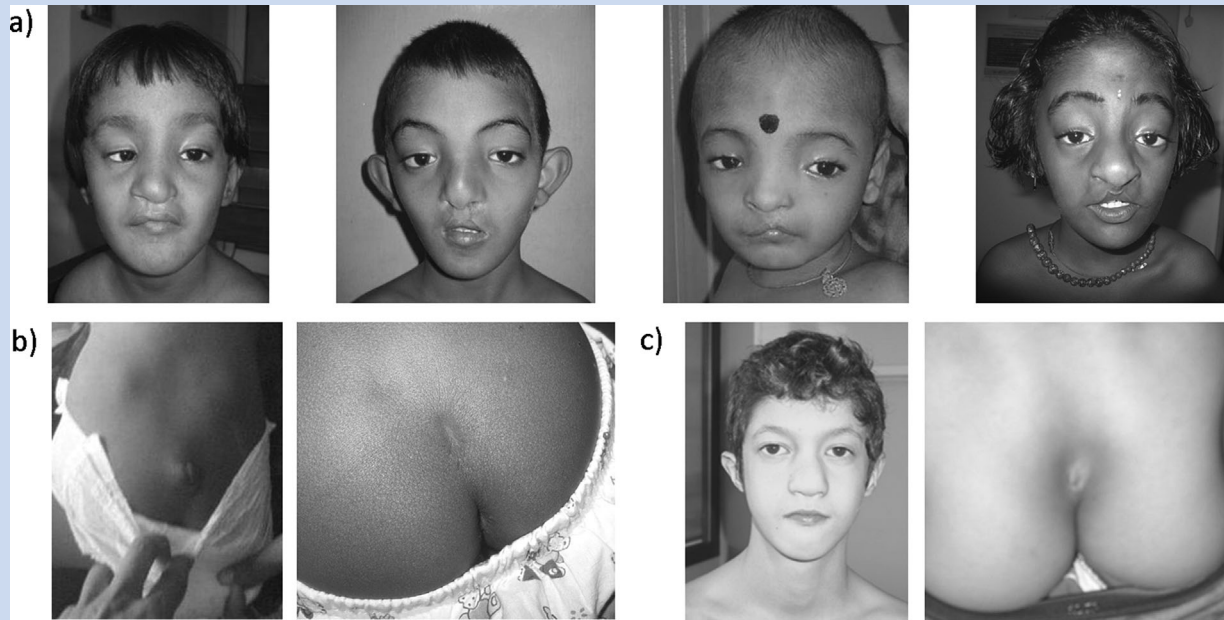
NA, not available; VSD, ventricular septal defect; ASD, atrial septal defect; ADHD, attention deficit hyperactivity disorder. Atypical cases are highlighted in gray.

<sup>a</sup>Twin.

<sup>b</sup>Short.

<sup>c</sup>Unilateral.

<sup>d</sup>Nasal speech.



**FIG. 1.** (a) Facial photographs of patients [L-R] 4–7 who all have *MASPI* mutations. Note characteristic facial appearance with repaired cleft lip and palate, hypertelorism and superiorly placed, arched eyebrows. (b) Sacral photographs for patients 6 (L) and 7 (R) showing caudal appendage and unusual sacrum, respectively. (c) Photographs of patient 11, who screened negative for *COLEC11* and *MASPI* mutations despite having suggestive facies, repaired cleft lip and palate and caudal abnormality.

genes were Sanger sequenced in individuals 5–7 and 9–13. As exome sequencing was available for individual 8 this was analyzed for changes in both genes with an average coverage of 91% at 10× across both genes.

This sequencing identified a homozygous frameshift mutation, c.637\_638delGC; p. (Ala213Leufs\*5), within the last exon of *COLEC11* (variant numbering according to NM\_024027.3) in siblings 1 and 2 (Fig. 2; Table I).

In addition homozygous *MASPI* mutations were identified in individuals 3–7 (all numbered according to NM\_139125.3) (Fig. 3; Table I). Further exploration of family history subsequently discovered that individuals 6 and 7 were also born to consanguineous parents. Three of the mutations identified were nonsense changes; the same change at c.760A>T; p. (Leu254\*) was identified in two unrelated individuals (5 and 6) and a c.9G>A; p. (Trp3\*) was identified in individual 4. The remaining two changes were missense alterations; the first of these was c.1987G>T; p. (Asp663Tyr) in individual 3. This occurred in the same exon as most of the previously reported mutations and is within a conserved residue. This amino acid change was predicted to be deleterious by SIFT [Ng and Henikoff, 2001], disease causing by Mutation taster [Schwarz et al., 2010] and probably damaging by Polyphen [Adzhubei et al., 2010]. The other missense change was c.547G>T; p. (Val183Leu) in individual 7. This change occurs in the last base of exon 4 and is predicted by Human Splicing Finder to remove the 5' splice site [Desmet et al., 2009]. No point mutations in either *COLEC11* or *MASPI* were identified in the remaining six individuals, including patients 8 and 11 who are considered to have a typical 3MC phenotype.

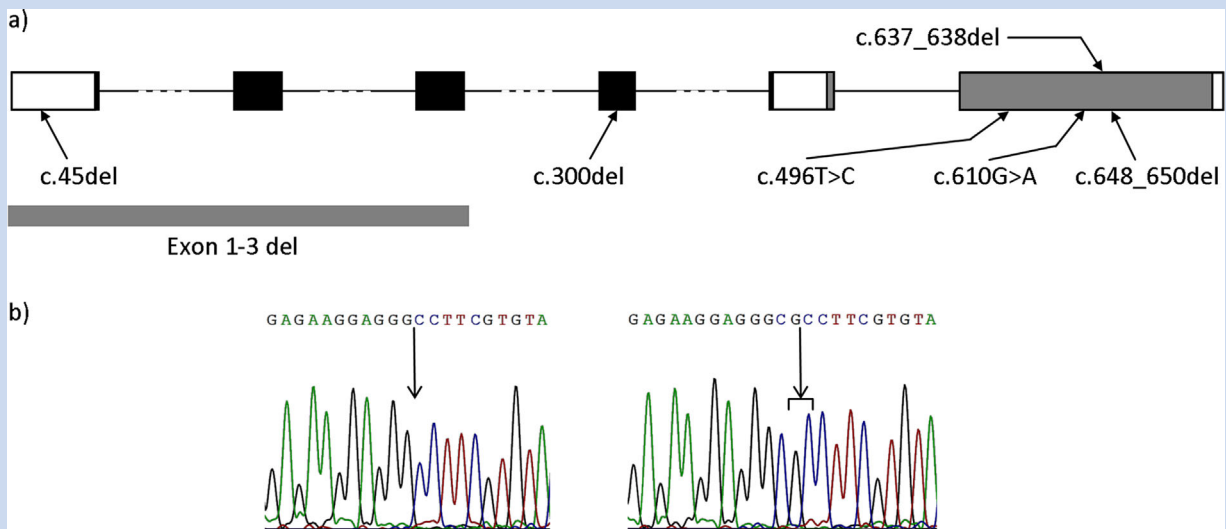
### CNV Analysis

Exome sequencing was carried out for individuals 8–13 who did not have point mutations in either *COLEC11* or *MASPI*. An analysis of this data for potential deletion/duplication events, which would not have been detected by Sanger sequencing, revealed no potential changes in these six individuals.

### Exome Sequence Analysis

For individuals 8 and 12, for whom SNP arrays were available, the exome sequencing was also analyzed to look for potential homozygous changes which may be causative of a 3MC phenotype. In all cases data were filtered to remove those variants with a frequency greater than 0.1% within the Exome Variant Server (~6,500 individuals), Exome Aggregation Consortium (>60,000 individuals), 1,000 Genome databases or those seen previously within an in house dataset of over 500 individuals before any further analysis. Within the one region of shared homozygosity between these two individuals there were no genes with variants in common after the data had been filtered as given above.

Gene prioritization was carried out for the separate homozygous regions identified in individuals 8 and 12 using Endeavor based on *COLEC11* and *MASPI* as training genes [Aerts et al., 2006]. An analysis of the exome data from both individuals based on the top 10 genes given by this prioritization revealed no changes after the data had been filtered as given above.



**FIG. 2.** Mutation analysis of *COLEC11*. [a] Representation of the *COLEC11* gene with positions of mutations identified in the current study (above) and those previously identified (below). Black boxes represent the collagen triple helix domain; gray boxes represent the c-type lectin domain. [b] Sanger sequencing of patient 1 (left) and WT sequence (right). Arrows mark the position of the c.637\_638delGC mutation. [Color figure can be seen in the online version of this article, available at <http://wileyonlinelibrary.com/journal/ajmga>].

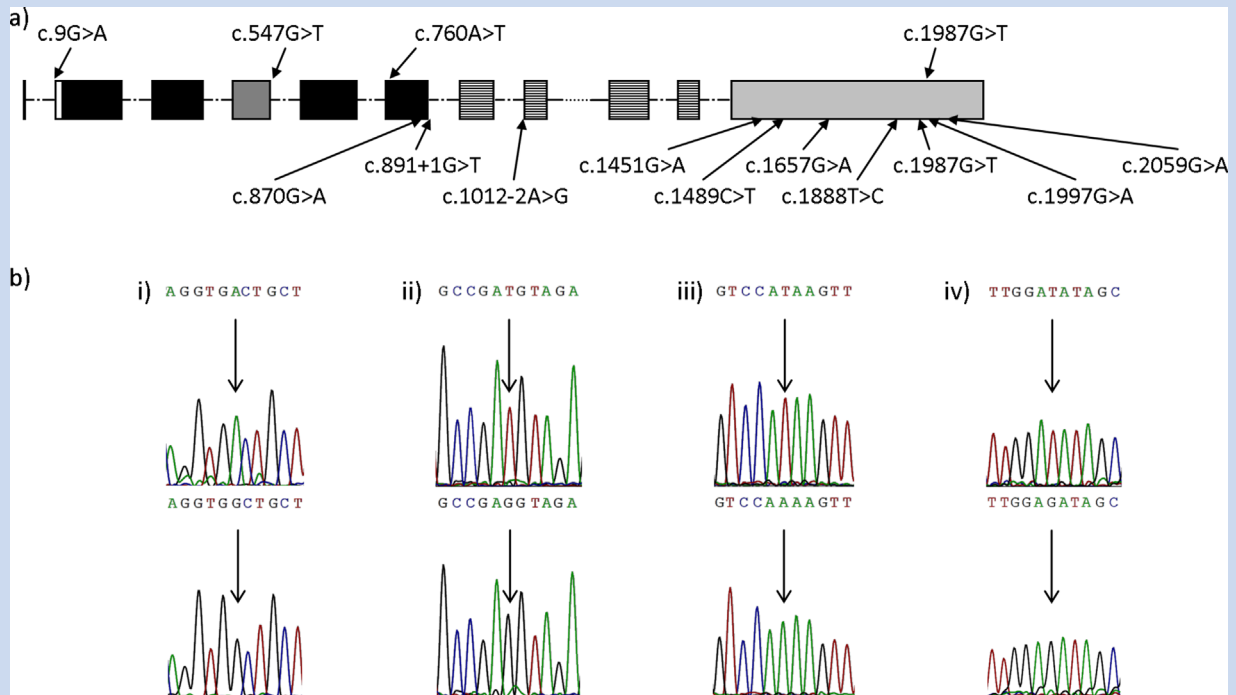
## DISCUSSION

It has been suggested that Malpuech syndrome should be considered as part of a wider disease spectrum known as 3MC syndrome along with Carnevale syndrome, Michels syndrome, and Mingarelli syndrome [Titomanlio et al., 2005, Leal et al., 2008]. This finding had been given further support by the identification of mutations within *COLEC11* and *MASPI* in individuals representing all four diagnoses [Sirmaci et al., 2010; Rooryck et al., 2011]. We report here the clinical and molecular findings in a further 13 individuals who have been suggested to have a diagnosis of Malpuech syndrome but all of which have features within the 3MC spectrum.

Our strategy for further investigation of the role of *COLEC11* and *MASPI* in 3MC syndrome was to carry out sequencing of both genes in those individuals where autozygosity mapping suggested a role for either gene or those individuals in whom mapping information was not available. We identified a single mutation within *COLEC11* in two siblings. This was a c.627\_628delGC; p. (Ala213Leufs\*5) change within exon 8 and so it is likely that no functional CL-K1 protein is present in these individuals. The report of these mutations brings the total number of *COLEC11* mutations identified in 3MC syndrome to seven within eight families (Fig. 2). Four of these are likely to result in no functional protein being produced either due to the removal of the first three exons or due to a frameshift leading to premature termination of the protein. The remaining three mutations reported by Rooryck et al. [2011] are either missense mutations or an in frame deletion within the carbohydrate recognition domain which would also be assumed to result in the loss of function of this domain. The studies of Bayarri-Olmos et al. [2015] offered further confirmation that *COLEC11* mutations affect serum levels of proteins in the complement pathway.

In addition we identified four novel mutations within *MASPI* bringing the total number of *MASPI* mutations identified in 3MC syndrome to 14 in 17 families (Fig. 3). *MASPI* is alternatively spliced, with the three isoforms, MASP-1 (NM\_001879.5), MASP-3 (NM\_139125.3), and Map44 (NM\_001031849.2) sharing exons 1–8 but differing in their carboxy terminals which contain different serine protease domains [Degn et al., 2009]. Exon 12 is unique to MASP-3 and is solely responsible for coding the serine protease domain of the MASP-3 isoform [Dahl et al., 2001]. Previously most 3MC mutations have been found within this exon and all are predicted to alter the activity of the serine protease domain either through disruption of the catalytic triad of the domain or through a disruption to the structure of the active site [Sirmaci et al., 2010; Yongqing et al., 2013]. The missense alteration, p. (Asp663Tyr), identified in the current study is the same as one reported by Atik et al. [2015]. It is the amino acid next to one of the catalytic triad (S664) and so it is likely that this change alters the enzymatic activity of this domain.

Interestingly the three other *MASPI* mutations identified in the current study, two nonsense and one splice site change, would likely result in nonsense mediated decay and so none of the three isoforms encoded by *MASPI* would be produced. There has been one previous report of a nonsense mutation within *MASPI* in an individual described as having Carnevale syndrome [Sirmaci et al., 2010] and a further two splice mutations in three individuals with 3MC syndrome [Atik et al., 2015]. Whilst these mutations would remove the serine protease domain of MASP-3 thought to be important in craniofacial development it would also remove the MASP-1 and Map44 isoforms which so far only have a known role in the complement pathway. We were unable to test complement function in these individuals but on specific questioning, none are known to have an immunological phenotype which would be



**FIG. 3.** Mutation analysis of *MASP1*. [a] Representation of all three isoforms of *MASP1* with positions of mutations identified in the current study (above) and those previously identified (below). Black boxes represent the CUB domains; dark grey boxes represent the EGF-like calcium binding domain; horizontal stripes represent the Sushi/CCP domains; light grey boxes represent the serine protease domain. [b] Sanger sequencing traces for mutations identified in *MASP1*. [i] Patient 4 (top) and WT (bottom). Arrows mark the position of the c.9G>A mutation. [ii] Patient 7 (top) and WT (bottom). Arrows mark the position of the c.547G>T mutation. [iii] Patient 5 (top) and WT (bottom). Arrows mark the position of the c.760A>T mutation. [iv] Patient 3 (top) and WT (bottom). Arrows mark the position of the c.1987G>T mutation. [Color figure can be seen in the online version of this article, available at <http://wileyonlinelibrary.com/journal/ajmga>].

consistent with impairment of the complement pathway suggesting that there is some functional redundancy in *MASP-1/Map44* function.

We have therefore been able to identify the probable genetic cause of 3MC syndrome within 7 out of the 13 individuals studied, and 7 out of 9 considered to have a typical clinical phenotype. This is contrary to the other studies of mutations in *COLEC11* and *MASP1* where mutations were identified in all individuals studied [Sirmaci et al., 2010; Rooryck et al., 2011; Atik et al., 2015]. A more likely alternative explanation is that those patients lacking identifiable mutations have a different, but overlapping condition. An analysis of the clinical features in those patients in our cohort who were mutation positive demonstrated they had more striking hypertelorism than the mutation negative patients and all had distinctive highly arched eyebrows with ptosis. This striking facial phenotype was also seen in the mutation positive patients described by Rooryck et al. [2011] and we therefore consider this as a key diagnostic feature for the condition. We found that a caudal appendage, usually taking the form of a cystic lesion over the sacrum was a good indicator for mutation positive individuals.

All of our patients had severe clefting of the lip and palate, though this was not seen in 11 of the previously reported cases with either *COLEC11* or *MASP1* mutations and so should not be seen as a

prerequisite for the clinical diagnosis of 3MC syndrome [Sirmaci et al., 2010; Rooryck et al., 2011; Atik et al., 2015]. Four of our patients with mutations had heights less than 3SD below the mean but not all had severe growth deficiency, and this was not a consistent feature in the previously reported patients. Similarly microcephaly is not always present. In addition craniosynostosis was seen in 7/16 patients by Rooryck et al and had been suggested to be more common in patients with *COLEC11* mutations but was not present in our patients although some abnormalities of skull shape were seen [Rooryck et al., 2011; Atik et al., 2015]. It is possible that these differences in phenotype between the various studies, particularly the differences in the amount of facial clefting, are due to the ascertainment bias when recruiting patients as all the individuals in the current study were initially referred as having Malpuech syndrome, where orofacial clefting is a key feature, and craniosynostosis is not common, rather than the broader 3MC syndrome. The abnormal skull shapes observed may also represent undiagnosed, but mild, craniosynostosis.

The degree of developmental delay/intellectual disability observed in mutation positive patients in the current study is mild rather than severe and Rooryck et al. [2011] reported some patients without cognitive impairment. Thus, severe intellectual disability would appear to argue against the diagnosis in 3MC syndrome. A rarer finding was laryngeal atresia in one of the

affected siblings (individual 2) who did not survive. One of our patients had radioulnar synostosis, confirming the association of this feature with the condition. As with the families described by Rooryck et al. [2011] we did not find specific phenotypic differences between those with *COLEC11* and *MASPI* mutations, though numbers remain small.

We were able to carry out autozygosity mapping on two patients (8 and 12) from consanguineous families who did not have mutations in either *MASPI* or *COLEC11*. Within these individuals there are a total of 43 regions greater than 2 Mb including one region in common between the two individuals. An analysis of exome sequencing data did not reveal any potential pathogenic variants within a shared gene within this common region. The Endeavor gene prioritization uses data from various sources to predict those genes most likely to be involved in a disease process based on a set of training genes [Aerts et al., 2006]. Using *COLEC11* and *MASPI* as training genes the top ten genes within both sets of homozygous regions were identified for patients 8 and 12. An analysis of these genes within the exome data from both individuals did not reveal any variants which were not seen at a frequency of less than 0.1% within various variant databases. Further analysis of the exome data from all individuals in the current study without *MASPI* and *COLEC11* mutations is required as it remains likely that there is at least one further gene mutated within 3MC syndrome.

Patients 9 and 10 when reviewed subsequently have both had a severe clinical course and as their facies have evolved over time they look less like those of 3MC syndrome. Therefore their diagnoses most likely lie elsewhere. Patient 12 is atypical in that she had an extremely low birth weight and much more severe postnatal growth failure than in other patients. Patient 13 has the unusual finding of bilateral radial aplasia and therefore Juberg-Hayward syndrome [Kantaputra and Mongkolchaisup, 1999], a further condition where overlap with the 3MC syndromes has been noted [Reardon et al., 2001], is being considered as an alternative diagnosis in this child. If these four cases are now considered not to be 3MC syndrome this would mean that mutations in either *MASPI* or *COLEC11* have been identified in 25 out of 27 families reported so far.

In summary, our findings confirm *MASPI* and *COLEC11* mutations as a common cause of 3MC and pick out some key clinical diagnostic features but demonstrate that this phenotype is heterogeneous and that it is possible that other genes, perhaps also involving the lectin complement pathway, will be discovered.

## ACKNOWLEDGMENT

Cleft research within the University of Manchester is supported by the Healing Foundation UK Cleft Cooperative.

## REFERENCES

Adzhubei IA, Schmidt S, Peshkin L, Ramensky VE, Gerasimova A, Bork P, Kondrashov AS, Sunyaev SR. 2010. A method and server for predicting damaging missense mutations. *Nat Methods* 7:248–249.

Aerts S, Lambrechts D, Maity S, Van Loo P, Coessens B, De Smet F, Tranchevent LC, De Moor B, Marynen P, Hassan B, Carmeliet P, Moreau Y. 2006. Gene prioritization through genomic data fusion. *Nat Biotechnol* 24:537–544.

Atik T, Koparir A, Bademci G, Foster J, II, Altunoglu U, Mutlu GY, Bowdin S, Elcioglu N, Tayfun GA, Atik SS, Ozen M, Ozkinay F, Alanay Y, Kayserili H, Thiel S, Tekin M. 2015. Novel *MASPI* mutations are associated with an expanded phenotype in 3MC1 syndrome. *Orphanet J Rare Dis* 10:128.

Bayarri-Olmos R, Hansen S, Henriksen ML, Storm L, Thiel S, Garred P, Munthe-Fog L. 2015. Genetic variation of *COLEC10* and *COLEC11* and association with serum levels of collectin liver 1 (CL-L1) and collectin kidney 1 (CL-K1). *PLoS ONE* 10:e0114883.

Carnevale F, Krajewska G, Fischetto R, Greco MG, Bonvino A. 1989. Ptosis of eyelids, strabismus, diastasis recti, hip defect, cryptorchidism and developmental delay in two sibs. *Am J Med Genet* 33:186–189.

Carr IM, Flintoff KJ, Taylor GR, Markham AF, Bonthron DT. 2006. Interactive visual analysis of SNP data for rapid autozygosity mapping in consanguineous families. *Hum Mutat* 27:1041–1046.

Dahl MR, Thiel S, Matsushita M, Fujita T, Willis AC, Christensen T, Vorup-Jensen T, Jensenius JC. 2001. *MASP-3* and its association with distinct complexes of the mannan-binding lectin complement activation pathway. *Immunity* 15:127–135.

Degn SE, Hansen AG, Steffensen R, Jacobsen C, Jensenius JC, Thiel S. 2009. *Map44*, a human protein associated with pattern recognition molecules of the complement system and regulating the lectin pathway of complement activation. *J Immunol* 183:7371–7378.

Desmet FO, Hamroun D, Lalande M, Collod-Beroud G, Claustres M, Beroud C. 2009. Human splicing finder: An online bioinformatics tool to predict splicing signals. *Nucleic Acid Res* 37:e67.

Kantaputra PN, Mongkolchaisup S. 1999. Juberg-Hayward syndrome: A new case report and clinical delineation of the syndrome. *Clin Dysmorphol* 8:123–127.

Leal GF, Silva EO, Duarte AR, Campos JF. 2008. Blepharophimosis, blepharoptosis, defects of the anterior chamber of the eye, caudal appendage, radioulnar synostosis, hearing loss and umbilical anomalies in sibs: 3MC syndrome? *Am J Med Genet Part A* 146A:1059–1062.

Malpuech G, Demeocq F, Palcoux JB, Vanlieferinghen P. 1983. A previously undescribed autosomal recessive multiple congenital anomalies/mental Retardation (MCA/MR) syndrome with growth failure, lip/palate cleft(s), and urogenital Anomalies. *Am J Med Genet* 16:475–480.

Michels VV, Hittner HM, Beaudet AL. 1978. A clefting syndrome with ocular anterior chamber defect and lid abnormalities. *J Pediatr* 93:444–446.

Mingarelli R, Castriota Scanderbeg A, Dallapiccola B. 1996. Two sisters with a syndrome of ocular, skeletal, and abdominal abnormalities (OSA syndrome). *J Med Genet* 33:884–886.

Ng PC, Henikoff S. 2001. Predicting deleterious amino acid substitutions. *Genome Res* 11:863–874.

Plagnol V, Curtis J, Epstein M, Mok KY, Stebbings E, Grigoriadou S, Wood NW, Hambleton S, Burns SO, Thrasher AJ, Kumararatne D, Doffinger R, Nejentsev S. 2012. A robust model for read count data in exome sequencing experiments and implications for copy number variant calling. *Bioinformatics* 28:2747–2754.

Reardon W, Hall CM, Gorman W. 2001. An atypical case suggesting the possibility of overlap between Malpuech and Juberg-Hayward syndromes. *Clin Dysmorphol* 10:123–128.

Rooryck C, Diaz-Font A, Osborn DP, Chabchoub E, Hernandez-Hernandez V, Shamseldin H, Kenny J, Waters A, Jenkins D, Kaissi AA, Leal GF, Dallapiccola B, Carnevale F, Bitner-Grindzicz M, Lees M, Hennekam R, Stanier P, Burns AJ, Peeters H, Alkuraya FS, Beales PL. 2011. Mutations



- in lectin complement pathway genes *COLEC11* and *MASPI* cause 3MC syndrome. *Nat Genet* 43:197–203.
- Sirmaci A, Walsh T, Akay H, Spiliopoulos M, Sakalar YB, Hasanefendioğlu-Bayrak A, Duman D, Farooq A, King MC, Tekin M. 2010. *MASPI* mutations in patients with facial, umbilical, coccygeal and auditory findings of Carnevale, Malpuech, OSA and Michels syndromes. *Am J Hum Genet* 87:679–686.
- Schwarz JM, Rödelsperger C, Schuelke M, Seelow D. 2010. MutationTaster evaluates disease-causing potential of sequence alterations. *Nat Methods* 7:575–576.
- Titomanlio L, Bennaceur S, Bremond-Gignac D, Baumann C, Dupuy O, Verloes A. 2005. Michels syndrome, Carnevale syndrome, OSA syndrome, and Malpuech syndrome: Variable expression of a single disorder (3MC syndrome)? *Am J Med Genet Part A* 137A:332–335.
- Yongqing T, Wilmann PG, Reeve SB, Coetzer TH, Smith AI, Whisstock JC, Pike RN, Wijeyewickrema LC. 2013. The x-ray crystal structure of mannose-binding lectin-associated serine proteinase-3 reveals the structural basis for enzyme inactivity associated with the Carnevale, Mingarelli, Malpuech, and Michels (3MC) syndrome. *J Biol Chem* 288:22399–22407.