

# Hepatic hemangioendothelioma: A rare case of a vascular tumour with slow progression

Tennakoon N

Faculty of Medicine, University of Kelaniya.

Correspondence to- Tennakoon N, Faculty of Medicine, University of Kelaniya,

E-mail: [tmnipuna95@gmail.com](mailto:tmnipuna95@gmail.com)

## Summary

Hemangioendothelioma is a vascular neoplasm which shows a borderline behaviour with slow progression. Primary epithelioid hemangioendotheliomas of the liver are rare tumours with an incidence rate of less than 1 per 1,000,000 population. The unpredictability of tumor behaviour, complicates the treatment. Main options for treatment are chemotherapy, radiotherapy and surgery. Due to the lack of established guidelines, there is a debate on the most effective surgical intervention. This case report describes a 46-year-old female patient who was undergoing chemotherapy for 8 years with a slowly progressing disease, finally diagnosed as a hemangioendothelioma and now being considered for further management in a surgical setting.

**Keywords** – hemangioendothelioma, treatment, outcome

## Introduction

Hemangioendothelioma (HE) is a vascular neoplasm which shows a borderline behaviour. It lies between benign haemangioma and malignant angiosarcoma<sup>1</sup>. HE mainly affects the liver, lungs, regional lymph nodes, peritoneum, bone, spleen and diaphragm. There are several types of HE such as intralymphatic angioendothelioma, retiform HE, kaposiform HE, epithelioid HE and pseudomyogenic HE<sup>3,2</sup>. Epithelioid HE are vascular tumors that may affect the liver, lungs, mediastinum, and multiple other sites. However, the most commonly involved organ is the liver. Primary Epithelioid Hemangioendotheliomas of the Liver (EHL) are rare tumours with an incidence rate of less than 0.1 per 100,000 population. Due to the low incidence, it is a poorly understood tumour. EHL has a predilection for females, with a female-to-male ratio of 3:2. It affects the right lobe of the liver more than the left lobe. These tumours may be asymptomatic (24.8%), or symptomatic, with right upper quadrant pain being the most common presenting symptom (48.6%). The lungs, regional lymph nodes, peritoneum, bone, spleen, and diaphragm are the most common sites of extra hepatic involvement<sup>3</sup>.

## Case Report

A 46-year-old lady presented with right hypochondrial pain, loss of weight, loss of appetite and back pain for six months in 2012.

She underwent an ultrasound scan which showed multiple liver metastases in both lobes of liver. An exploratory laparotomy was done and biopsies showed fibrous tissue with scattered chronic inflammatory cells. Computed Tomography (CT) scan chest and abdomen showed multiple deposits in both lungs and both lobes of liver. She underwent further biopsies which demonstrated a HE. Later she was started on chemotherapy, the disease was slowly progressing over the time. She underwent two sessions of Transarterial Chemoembolization (TACE) in 2019 and 2020. The recent Positron Emission Tomography (PET) scan in 2021 showed a bilateral disease, almost completely occupying the liver (figure 1 and 2). There was no activity in the lungs.

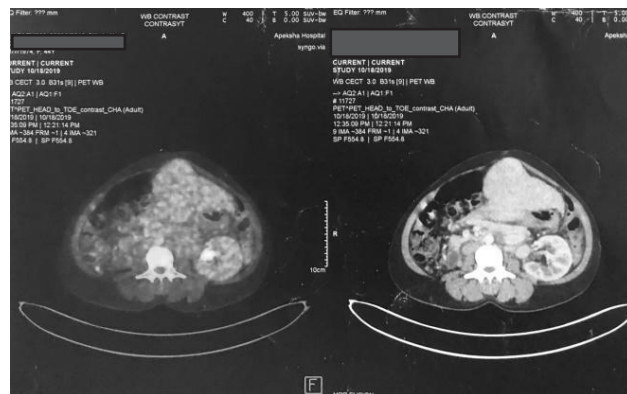


Figure 1: PET scan demonstrating a large multinodular hepatic lesion with metabolic activity similar to that of the background liver.

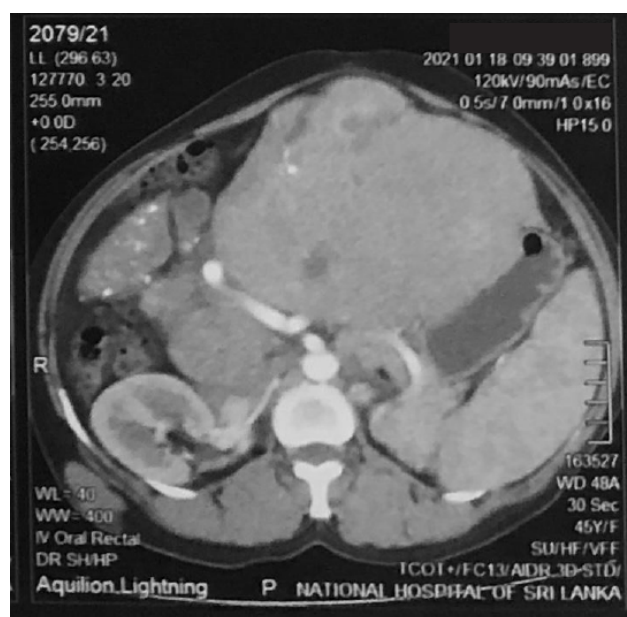


Figure 2: CT of the abdomen demonstrating bilateral disease

## Discussion

In this patient EHL has progressed slowly over 9 years despite treatment, eventually almost completely occupying liver parenchyma. Main treatment options for EHL are chemotherapy, radiotherapy and surgery. In fact, many studies reported that there was no significant difference in 5-year survival rates among the different treatments<sup>3</sup>. However, the general consensus is to begin with observation to assess tumour behaviour before intervention, if applicable at all.

The surgical interventions for EHL include hepatic resection, hepatic transplantation and hepatic artery ligation<sup>4</sup>. The hepatic resection is done for single, intrahepatic and resectable lesions. Liver transplant is done for patients with multiple bilobar hepatic lesions. Due to the lack of established guidelines for EHL management, there has been a debate on the most effective surgical intervention. Rodriguez et al.<sup>5</sup> argued that liver transplants should be adopted at higher rates due to EHL's ability to metastasize, its' difficulty to resect, and to avoid liver failure in complicated intrahepatic disease. Some studies provide conflicting recommendations for extrahepatic disease. A clear criterion for surgical procedures is yet to be established. Larger studies have demonstrated that hepatic resection has better overall survival rates than liver transplants. Mehrabi et al.<sup>6</sup> reported that the 5-year survival rate of patients that underwent hepatic resection is 75% and liver transplants 54.5%.

Grotz et al.<sup>7</sup> reported 86% and 73% 5-year survival rates, respectively. Simultaneously, 5-year disease free survival is higher in hepatic resection, compared to liver transplants, at 62% and 46% respectively. However, due to higher number of hepatic resections compared to liver transplants, large patient cohort studies are required to achieve statistically significant results<sup>3</sup>.

Interestingly, a retrospective study of 149 patients from the European Liver and Transplant Registry proposed a Hepatic endothelioid hemangioendothelioma - liver transplant scoring system to predict the risk of post-transplant recurrence.

This study recommended liver transplants rather than observation as the main intervention due to better prognosis and concluded that extrahepatic disease was not found to be a significant risk factor. In fact, this study suggested that lymph node metastasis should not necessarily delay liver transplant. Macrovascular invasion, waiting time of 120 days or less for transplant, and hilar lymph node invasion were all found to be risk factors for post-transplant recurrence in multivariate regression analysis.

This can potentially impact the management of EHL, since macrovascular invasion can be detected before transplant, but imaging modalities still need further refinement to increase sensitivity and specificity. This scoring system has the potential to guide health care providers on whether or not to pursue liver transplant and to determine the frequency of post-transplant follow up<sup>8</sup>.

## Reference

1. Requena L, Kutzner H. Hemangioendothelioma. *Seminars in Diagnostic Pathology*. 2013; 30(1): 29–44.
2. Mentzel T. Hemangioendotheliomas--evolution of a concept of a heterogeneous group of vascular neoplasms. *Verh Dtsch Ges Pathol*. 1998;82(1):99-111.
3. Virarkar M, Saleh M, Diab R, Taggart M, Bhargava P, Bhosale P. Hepatic hemangioendothelioma. *World Journal of Gastrointestinal Oncology*. 2020;12(3):248–56
4. Redaelli D, Guraya SS. Primary hemangioendothelioma of liver; report of a case and review of literature. *J Taibah University Medical Science*. 2015;10(2):243–7
5. Rodriguez JA, Becker NS, O'Mahony CA, Goss JA, Aloia TA. Long-term outcomes following liver transplantation for hepatic hemangioendothelioma: The UNOS experience from 1987 to 2005. *J Gastrointestinal Surgery*. 2008;12(1) :110–6.
6. Mehrabi A, Kashfi A, Fonouni H, Schemmer P, Schmieid BM, Hallscheidt P, et al. Primary malignant hepatic epithelioid hemangioendothelioma: A comprehensive review of the literature with emphasis on the surgical therapy. *Cancer*; 2006;107(9):2108–21.
7. Grotz TE, Nagorney D, Donohue J, Que F, Kendrick M, Farnell M, et al. Hepatic epithelioid haemangioendothelioma: is transplantation the only treatment option? *hepato biliary pancreatic sciences*. 2010;12(8):546–53.
8. Lai Q, Feys E, Karam V, Adam R, Klempnauer J, Oliverius M, et al. Hepatic epithelioid hemangioendothelioma and adult liver transplantation: Proposal for a prognostic score based on the analysis of the eltr-elita registry. *Transplantation*. 2010;101(3):555–64.