

Cross-fused right-to-left renal ectopia presenting as hypertension in a three-year-old

Udara Sandakelum¹, Ruwan Samarathna¹, Ishara Kumarasiri¹, Reha Balasubramaniam¹, *Sachith Mettananda^{1,2}

Sri Lanka Journal of Child health, 2023; 52(2): 245-248

DOI: <https://doi.org/10.4038/sljch.v52i2.9862>

(Keywords: Cross-fused renal ectopia, Hypertension, Renal arteries)

Introduction

Cross-fused renal ectopia (CFRE) is a rare congenital anomaly of the kidneys that can remain asymptomatic for several years. It is commoner in boys than in girls, and left-to-right is more frequent than right-to-left. The usual clinical presentation is recurrent urinary tract infection due to associated hydronephrosis, vesicoureteral reflux or other structural anomalies^{1,2}. CFRE presenting as hypertension is rare³. Here we report a three-year-old girl with right-to-left CFRE presenting as hypertension.

Case presentation

A three-year-old previously well girl was admitted for further evaluation of hypertension incidentally detected during a febrile illness. She was born at term to non-consanguineous parents with a birth weight of 2.4 kg, and she did not have perinatal complications. There was no history of urinary tract infections or family history of renal tract anomalies.

On examination, she was well, active and not pale. Her weight was 16 kg (between median and +1SD), and her height was 101 cm (between median and

+1SD). She had stage 1 hypertension with a blood pressure of 118/78 mmHg. The rest of the cardiovascular system examination was normal. The abdominal examination did not reveal organomegaly or ballotable masses. Nervous system examination, including fundoscopy, was normal.

She was investigated to identify the cause for the hypertension. The biochemistry revealed a serum creatinine of 42 μ mol/L (normal: 55-100 μ mol/L), a serum sodium of 135 mmol/L (normal: 135-148 mmol/L), a serum potassium of 3.6 mmol/L (normal: 3.5-5.2 mmol/L), a serum aldosterone in the upright position of 3.24 ng/dl (normal: 2.5-39.2 ng/dl), plasma renin activity in the upright position of 5.4ng/ml/hour and an aldosterone to renin ratio of 0.6 (normal: <30). Her urine full report and urine culture were normal. The creatinine clearance was 110 ml/min/1.73m².

Abdominal ultrasonography revealed an empty right renal bed with a right kidney on the left side attached to the lower pole of the left kidney. The echogenicity of the kidneys was normal with preserved cortico-medullary demarcation. Renal artery Doppler was normal. Computed tomography (CT) scan confirmed a right inferior type CFRE without hydronephrosis, calculi, kinking or stenosis of renal arteries (Figure 1).

Three arteries from the aorta supplied the renal bed. Orthoptic normal size ureters were noted on ultrasonography and CT intravenous urography (Figure 2).

Dimercaptosuccinic acid (DMSA) scintigraphy confirmed the right to left CFRE without cortical defects suggestive of renal scarring (Figure 3). The micturating cystourethrogram (MCUG) did not show vesicoureteral reflux.

¹University Paediatrics Unit, Colombo North Teaching Hospital, Ragama, Sri Lanka,

²Department of Paediatrics, Faculty of Medicine - University of Kelaniya, Ragama, Sri Lanka

*Correspondence: sachith.mettananda@kln.ac.lk



orcid.org/0000-0002-0760-0418

(Received on 05 October 2021. Accepted after revision on 19 November 2021)

The authors declare that there are no conflicts of interest

Personal funding was used for the project.

Open Access Article published under the Creative

Commons Attribution CC-BY  License

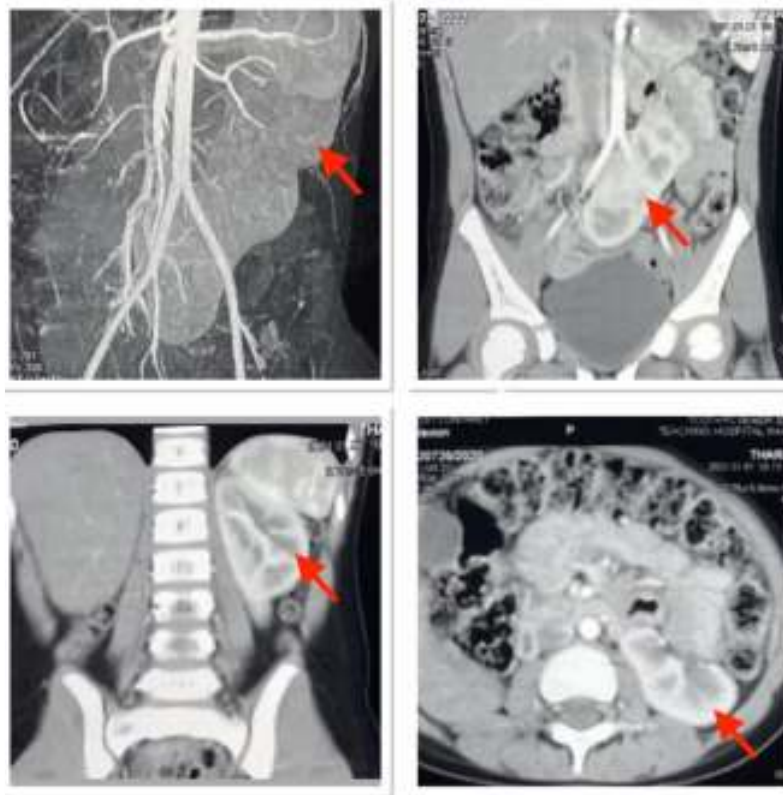


Figure 1: CT images showing right-to-left cross-fused renal ectopia (red arrow)

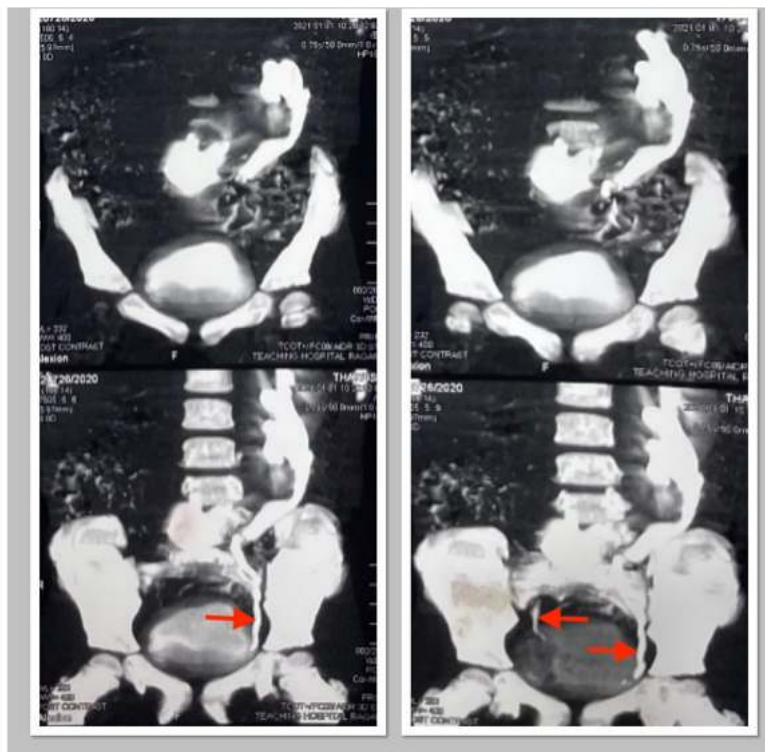


Figure 2: CT intravenous urogram showing cross-fused renal ectopia with orthoptic normal size ureters (red arrow)

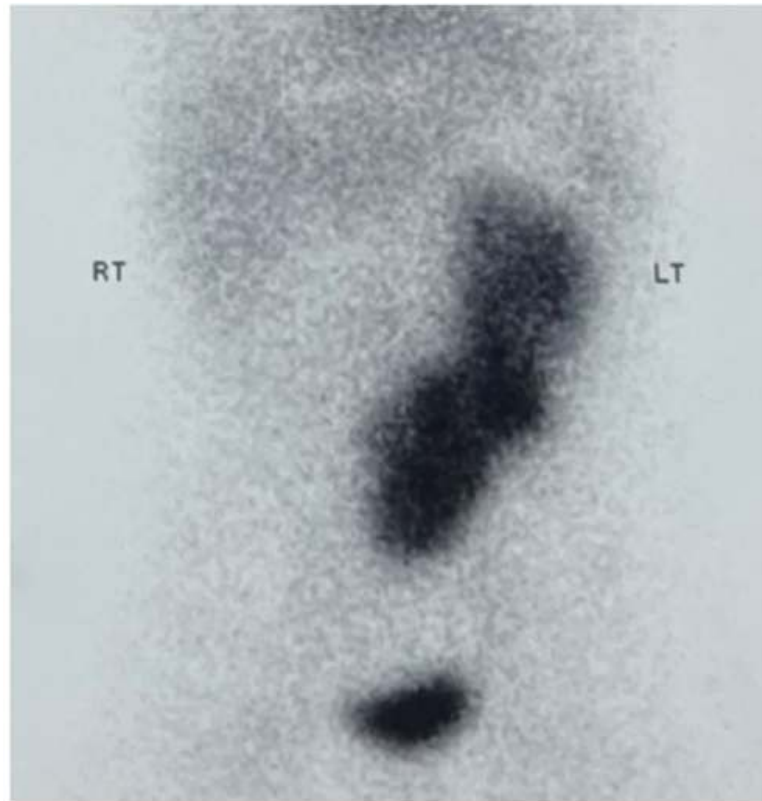


Figure 3: DMSA scan confirming cross-fused renal ectopia with no evidence of renal scarring

Discussion

CFRE is a rare renal malformation that is associated with ureteric abnormalities like hydronephrosis and vesico-ureteral reflux⁴. It commonly presents with recurrent urinary tract infections. This case report describes a 3-year-old girl presenting with stage 1 hypertension, a rare presentation of CFRE. In this child, CFRE was revealed only following investigations performed to identify the cause for hypertension.

Hypertension has been previously reported with CFRE. However, in all these instances, there were other renal abnormalities to cause hypertension. Mininberg DT, *et al*³ reported an infant with CFRE and hypertension due to narrowing in one of the two renal arteries supplying the fused kidney³. In a rare presentation of a superior ectopia type CFRE, hypertension was reported due to focal stenosis of the right main renal artery¹. In contrast, there were no renal artery or ureteric abnormalities to cause hypertension in our patient.

The mechanism of hypertension in this girl is unclear. Her renal functions were within normal limits, and she did not have ureteric abnormalities or renal scarring in imaging studies. The CT arteriogram excluded renal artery stenosis and

kinking of renal arteries. However, the renal bed of this patient was unusually supplied by three renal arteries originating from the aorta. This abnormal composition and orientation of renal arteries could be the cause of hypertension. During embryonic development, kidneys ascend from the sacral region to the lumbar region. The renal hila undergo rotation during this physiological ascent and the blood supply changes from common iliac arteries to abdominal aorta⁵. Therefore, rotation of the renal arteries without stenosis could be the cause of hypertension in this patient.

In conclusion, this case report describes a child with CFRE presenting with hypertension. It highlights that hypertension could occur in CFRE even without ureteric or gross renal artery abnormalities. It also emphasizes the importance of routine blood pressure measurement in children, which could lead to detection of important structural abnormalities.

References

1. Leyla A, Ali KO, Tarkan E, Ihsan E. The rarest of the rare: Crossed fused renal ectopia of the superior ectopia type, *Hindawi - Case Reports in Nephrology* 2015; 2015: Article ID 742419.

- <https://doi.org/10.1155/2015/742419>
PMid: 26064722 PMCID: PMC4429221
2. Loganathan AK, Bal HS, Crossed fused renal ectopia in children: a review of clinical profile, surgical challenges, and outcome. *Journal of Pediatric Urology* 2019; **15**(4): 315-21.
<https://doi.org/10.1016/j.jpuro.2019.06.019>
PMid: 31331806
 3. Mininberg DT, Roze S, Pearl M. Hypertension associated with crossed renal ectopia in an infant. *Pediatrics* 1971; **48**: 454-7
 4. Paul A, Courtney KR, Chapter - Developmental Abnormalities of the Genitourinary System, Juul, Avery's Diseases of the Newborn (Tenth Edition), Elsevier, 2018, Pages 1260 -1273.e4, ISBN9780323401395,
<https://doi.org/10.1016/B978-0-323-40139-5.00088-7>
 5. Francesca DG, Eliseo P, Adriano L, Alessio B, Yuri C, Francesco G, et al. Congenital kidney malformation: Computed tomography and scintigraphy findings of renal reversed rotation, *Radiology Case Reports* 2019; **14**(6): 678-82.
<https://doi.org/10.1016/j.radcr.2019.03.004>
PMid:30976367 PMCID:PMC6439229