

*Case Report***The first reported case of co-infection of imported hepatitis E and *Plasmodium falciparum* malaria in Sri Lanka**S Senarathne¹, S Rajapakse², HJ de Silva³, S Seneviratne⁴, P Chulasiri⁵, D Fernando⁵*Sri Lankan Journal of Infectious Diseases 2023 Vol.13(2):E47:1-5*DOI: <https://doi.org/10.4038/sljid.v13i2.8570>**Abstract**

Global travel and tourism, especially across tropical countries, may lead to importation of malaria and other infectious diseases into Sri Lanka. This case report describes the first co-infection of imported hepatitis E and *Plasmodium falciparum* malaria in a tourist diagnosed in Sri Lanka. The patient was initially diagnosed with uncomplicated *P. falciparum* malaria and was started on treatment with oral Artemisinin-based Combination Therapy (ACT). Deterioration of hepatic enzymes and hyperbilirubinaemia despite the rapid parasitological response to antimalarials led to further investigation and diagnosis of co-infecting hepatitis E in this patient. The importance of clinicians being vigilant on travel associated co-infections is highlighted to ensure early diagnosis and better patient management.

Keywords: Plasmodium falciparum, malaria, hepatitis E, co-infections, hyperbilirubinaemia

Introduction

Sri Lanka received malaria free certification by the World Health Organization in 2016.¹ However, imported malaria continues to be a threat to the re-establishment of the disease and tourists are identified as a high-risk group for importing malaria to Sri Lanka.¹ Approximately 50 imported

¹ Department of Parasitology, Faculty of Medical Sciences, University of Sri Jayewardenepura, Gangodawila, Nugegoda, Sri Lanka.

² Department of Clinical Medicine, Faculty of Medicine, University of Colombo, No.25, P.O. Box. 271, Kynsey Road, Colombo 8, Sri Lanka

³ Department of Medicine, Faculty of Medicine, University of Kelaniya, P.O Box 6, Thalagolla Road, Ragama, Sri Lanka

⁴ Anti Malaria Campaign, Public Health Complex, 555/5, Elvitigala Mawatha, Colombo 05, Sri Lanka

⁵ Department of Parasitology, Faculty of Medicine, University of Colombo, No.25, P.O. Box. 271, Kynsey Road, Colombo 8, Sri Lanka

Address for correspondence: Prof Deepika Fernando, Department of Parasitology, Faculty of Medicine, University of Colombo, No.25, P.O. Box. 271, Kynsey Road, Colombo 8, Sri Lanka: Email: deepika@parasit.cmb.ac.lk; Telephone: +94 717229509

 <https://orcid.org/0000-0002-2535-9031>

Received 3 February 2023 and revised version accepted 28 August 2023. Published on 9 October 2023



This is an open-access article distributed under the terms of the Creative Commons Attribution License, which permits unrestricted use, distribution, and reproduction in any medium, provided the original author and source are credited.

malaria cases are reported annually with a higher number of *Plasmodium falciparum* and *P. vivax* cases.¹

Hepatitis E is a travel associated infection transmitted by the faeco-oral route in the developing world, mainly by ingestion of contaminated drinking water.² However, it is a rare disease in Sri Lanka and there is no data available on its prevalence at a national level.³ Co-infection of hepatitis E and *P. falciparum* malaria are rarely reported in the literature.⁴ This is the first reported case in Sri Lanka of a patient co-infected with both hepatitis E and *P. falciparum* malaria, and both infections were imported.

Case report

A 21-year-old apparently healthy Swiss national arrived in Sri Lanka after a two month stay in India as part of a world tour. On the 4th day after arrival, he developed fever with chills, headache, nausea, and vomiting. Due to worsening of these symptoms, he was admitted to a hospital on the following day. He also complained of loss of appetite, body weakness, abdominal pain, and dark-coloured urine. On examination, he was febrile (40 °C) and flushed. Abdominal examination revealed a tender splenomegaly but no hepatomegaly which was also confirmed by ultrasonography. Cardiovascular, respiratory, and neurological examinations were unremarkable. Full blood count showed thrombocytopenia ($87 \times 10^3/\text{mm}^3$), 89% neutrophils, and 9% lymphocytes (total leukocyte count: $7670 \text{ cells}/\text{mm}^3$). Blood picture was suggestive of a viral infection. C-Reactive Protein was elevated to 45.3 mg/L. Liver function tests showed elevated hepatic enzymes (ALT: 190 U/L, AST: 213 U/L, GGT: 179 U/L) and hyperbilirubinaemia (total bilirubin: 6.78 mg/dL, direct bilirubin: 4.85 mg/dL, indirect bilirubin: 1.93 mg/dL). His urine sample was positive for bile pigment. Renal function tests were normal except for an elevated blood ammonia level (85 $\mu\text{mol}/\text{L}$).

Suspecting an infectious aetiology causing hepatic injury, he was screened for COVID-19, dengue, hepatitis A, hepatitis B, hepatitis C, Epstein-Barr virus, and cytomegalovirus, but all were negative. After sending blood for culture, he was started on intravenous ceftriaxone and oral doxycycline. Despite treatment, the patient continued to have high fever spikes. On the second day after admission, considering the fact that he had spent 2 months in India while not on malaria chemoprophylaxis, his blood was tested for malarial antigens. The rapid diagnostic test (MeriScreen™) yielded a positive result for *P. falciparum* antigen (a pale HRP2 band) and microscopy detected *P. falciparum* ring stages only with a parasite density of 120/ μl (Figure 1).

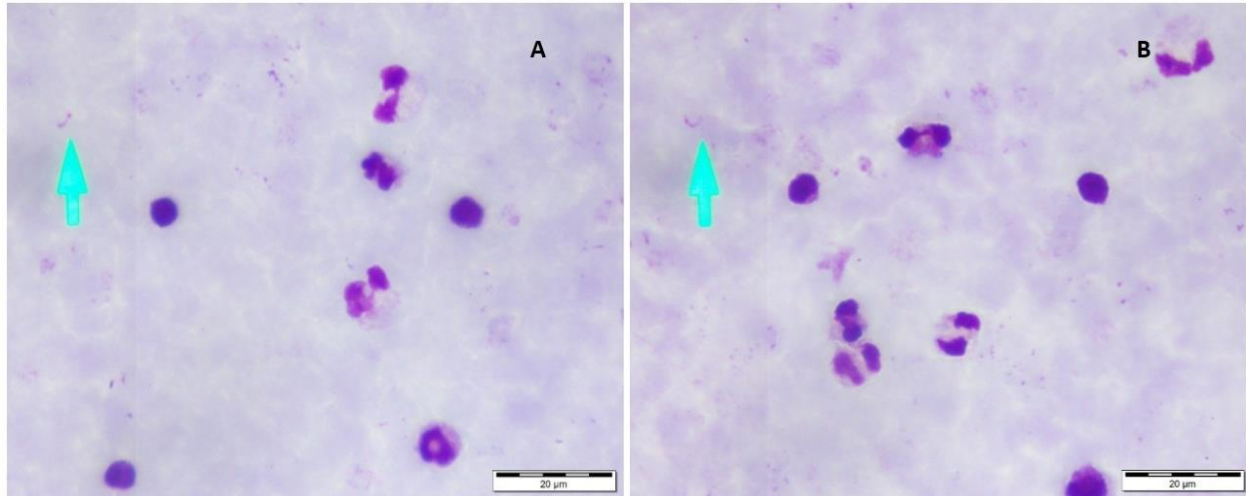


Figure 1. Photomicrographs of the Giemsa-stained thick blood smear of the patient under x1000 magnification. In A and B, the arrow shows *Plasmodium falciparum* ring stage.

Based on clinical and laboratory evidence, a diagnosis of uncomplicated *P. falciparum* malaria was made, doxycycline was omitted, and the patient immediately started on oral Artemisinin-based Combination Therapy (ACT), a combination of 20 mg of artemether and 120 mg of lumefantrine, 6 dose regime over 3 days. One day later, the patient became afebrile and malaria parasites were not detected in blood smears. However, his liver functions continued to deteriorate (ALT: 250 U/L, AST: 175 U/L, ALP: 130 U/L, GGT: 179 U/L; total bilirubin: 10.65 mg/dL; direct bilirubin: 8.08 mg/dL; indirect bilirubin: 2.57 mg/dL). Jaundice was apparent and he was started on oral ursodiol. Blood culture had no growth after 5 days of incubation. He was tested for hepatitis E virus (HEV) specific IgM antibodies by a sandwich enzyme-linked immunosorbent assay (ELISA) (specificity 96.9% and sensitivity 92.9% according to the manufacturer, International Immuno Diagnostics) and found to be positive. No specific antiviral treatment was given. Following completion of ACT for 3 days, as the patient was clinically well, he was given a stat dose of primaquine and discharged from hospital with a follow-up plan for malaria microscopy and advice on adequate rest for recovery from HEV infection. The timeline of his illness is given in Figure 2.

Day 1	Day 2	Day 3	Day 4	Day 5	Day 6	Day 7	Day 8	Day 9	Day 10
Arrival in Sri Lanka			Onset of fever and other symptoms	Admission to hospital	Diagnosis of malaria Oral ACT started	Blood negative for malaria parasites Marked jaundice Oral ursodiol started		Diagnosis of hepatitis E Oral ACT completed Primaquine stat dose	Discharge from hospital

Figure 2. Timeline of important events of the case report

Discussion

India was the only malaria endemic country this tourist visited until his arrival in Sri Lanka. Since the minimal incubation period for *P. falciparum* is 7 days,⁵ it can be concluded that this patient acquired malaria from India because he developed the first episode of fever on day 4 after arrival in Sri Lanka.

In severe *P. falciparum* infection, hyperbilirubinaemia is not unusual since it can occur due to intravascular hemolysis of parasitised and non-parasitised red blood cells, disseminated intravascular coagulation, and hepatic dysfunction.⁶ However, this patient had uncomplicated *P. falciparum* malaria with rising levels of both direct and indirect bilirubin despite a good parasitic response to ACT, indicating a hepatic phase impairment. A co-existing acute hepatitis or underlying chronic hepatitis was therefore strongly suspected and on appropriate investigations he was found to be positive for Hepatitis E specific IgM antibody. Although the detection of IgM alone is not diagnostic of acute HEV infection as the positive IgM could last for up to 4-6 months⁷, since HEV has a minimal incubation period of 2 weeks⁸, it is very likely that he acquired his infection in India or countries he travelled to prior to arriving in Sri Lanka. India is highly endemic for HEV as 60% of blood donors have shown prior exposure.⁹ In India, Hepatitis E is caused exclusively by HEV genotype 1, and there is no specific antiviral treatment.⁹

A reactive IgM result needs to be confirmed by either a reactive IgG or a positive HEV RNA testing.¹⁰ However, both IgG and HEV RNA testing could not be performed in this patient, as the patient was about to leave the country and RNA testing for HEV was unavailable in Sri Lanka.

In conclusion, this is the first reported case of co-infection of hepatitis E and *P. falciparum* malaria in Sri Lanka, both of which were imported. Clinicians should be vigilant and not disregard the possibility of other travel associated co-infections in patients with imported malaria. If hepatic enzymes are unduly elevated and there is both direct and indirect hyperbilirubinaemia, another aetiology for hepatic injury should be sought in order to obtain a favourable outcome in such patients.

Declarations

Acknowledgement: We thank Dr. Kumudu Gunasekara, Parasitologist, Anti Malaria Campaign for her courtesy in providing photomicrographs for this manuscript.

Conflicts of Interest: There are no conflicts of interest

Funding: None

Ethics statement: Ethical approval to report significant findings with regard to individuals diagnosed with malaria in Sri Lanka has been obtained from the Ethics Review Committee, Faculty of Medicine, University of Colombo (ERC-18-084)

Authors' contributions: SR and HJS clinically managed the patient. ShS and PC provided guidance and advised on patient management. SuS and DF prepared the manuscript.

References

1. Dharmawardena P, Premaratne R, Wickremasinghe R et al. Epidemiological profile of imported malaria cases in the prevention of reestablishment phase in Sri Lanka. *Pathog Glob Health*. 2022; 116(1):38-46. doi:10.1080/20477724.2021.1951556
2. Webb GW, Kelly S, Dalton HR. Hepatitis A and Hepatitis E: Clinical and Epidemiological Features, Diagnosis, Treatment, and Prevention. *Clin Microbiol Newsl*. 2020; 42(21):171-179. doi:10.1016/j.clinmicnews.2020.10.001

3. Wijewantha HS. Liver Disease in Sri Lanka. *Euroasian J Hepatogastroenterol*. 2017; 7(1):78-81. doi:10.5005/jp-journals-10018-1217
4. Sahra S, Jahangir A, Iqbal QZ et al. Co-infection of hepatitis E virus and Plasmodium falciparum malaria: A genuine risk in sub-Saharan Africa. *Parasites Vectors* 2021; 14: 215. doi: <https://doi.org/10.1186/s13071-021-04723-4>
5. Centers for Disease Control and Prevention, 2022. Available at: <https://www.cdc.gov/malaria/about/>. Accessed October 23, 2022.
6. Anand AC, Puri P. Jaundice in malaria. *J Gastroenterol Hepatol*. 2005;20: 1322-1332. doi: <https://doi.org/10.1111/j.1440-1746.2005.03884.x>
7. Samer S. El-Kamary, G. Thomas Strickland, Hepatitis, Viral, Editor(s): Stella R. Quah, International Encyclopedia of Public Health (Second Edition), Academic Press, 2017, Pages 611-620, ISBN 9780128037089, doi: <https://doi.org/10.1016/B978-0-12-803678-5.00209-5>.
8. Azman AS, Ciglenecki I, Oeser C et al. The incubation period of hepatitis E genotype 1: insights from pooled analyses of travellers. *Epidemiol Infect*. 2018;146(12):1533-1536. doi:10.1017/S0950268818001097
9. Aggarwal R, Goel A. Hepatitis E: Current Status in India. *Clin Liver Dis* 2021;18: 168-172. doi: <https://doi.org/10.1002/cl.1146>
10. National Infection Service, Public Health England, 2018. UK Standards for Microbiology Investigations Screening and monitoring for hepatitis E infection. *Virology* | V 53 | Issue no: 1. Available at: <https://www.gov.uk/government/publications/smi-v-53-screening-for-hepatitis-e-infection>. Accessed July 7, 2023.