

# Comparing two different presentations of Takayasu arteritis

Kurukulasuriya SAF<sup>1\*</sup> , Munidasa D<sup>2</sup>

## Abstract

Reported here are two Asian patients with Takayasu arteritis (TA) with contrasting presentations and responses to treatment. The first patient was a 53-year-old man who presented with disabling abdominal pain. Imaging revealed thickening of the coeliac axis extending to common hepatic and splenic arteries causing external compression with luminal narrowing. There was uniform thickening of the aortic arch and the wall of the descending aorta along with retroperitoneal fibrosis. Early treatment resulted in almost complete remission in eight weeks. The second patient was a 48-year-old woman with pain down the left upper limb with eventual ischaemia of the fourth finger. Imaging revealed circumferential wall thickening at the origin of the left subclavian artery. Treatment started after 3 weeks of the initial presentation, and took up to 14 months for clinical improvement. The relative rarity of this disease and the heterogeneous nature of its clinical manifestations predispose to late diagnosis and delayed treatment. Clinical suspicion and relevant imaging are crucial for the early and accurate diagnosis and management of patients with TA.

**Keywords:** Takayasu arteritis, abdominal pain, retroperitoneal fibrosis

## Introduction

Takayasu arteritis (TA) is a large vessel arteritis that mainly involves the aorta and its branches. In this relatively rare disease, the abdominal aorta and its branches tend to be affected in men, whereas in women involvement of the thoracic aorta and its branches is encountered more commonly.(1)

Depending on the vessel that presents the occlusive or stenotic lesions or aneurysmal dilatations, clinical manifestations vary. Interestingly, the involvement of the aortic arch is referred to as the Japanese form while the involvement of the descending thoracic or abdominal aorta and its branches is known as the Indian form. The subclavian and innominate arteries are by far the most common sites of stenosis. Involvement of coronary arteries is also recognised. Isolated pulmonary arterial stenosis(2) has been reported. Renovascular hypertension due to disease

of the renal arteries(3) is seen in the paediatric age group.

In the adult TA patient, involvement of the renal arteries is common, explaining the elevated incidence of hypertension, which is encountered more frequently in the Asian patient. Heart failure and uncontrolled hypertension due to abdominal aortic thrombosis has been reported.(4)

The pathogenesis of TA is mainly due to abnormal cell-mediated immunity(5) CD4+ T cells, CD8+ T cells, Th17 cells, NK cells,  $\gamma\delta$  T lymphocytes and granulocytes have been recognised in the cellular infiltrate.(6) Involvement of the humoral immune response is also recognised in TA.(7)

It is recognised that TA coexists with inflammatory bowel disease (IBD). The two diseases may have common genetic backgrounds and molecular

### \*Correspondence:

Sujeevani Kurukulasuriya  
Senior Lecturer in Pharmacology  
University of Kelaniya, Sri Lanka  
E-mail: [sujeeku@gmail.com](mailto:sujeeku@gmail.com)

Full list of author information is available at the end of the article



pathways. This may influence treatment decisions.(8) Eshed et al. suggest that IBD and sacroiliitis should be routinely screened for in the TA patient.

Large-artery biopsies cannot easily be done in patients with suspected TA. The non-specificity of clinical presentations, can vary from asymptomatic disease to severe cardiac failure, and cause delayed treatment.(9) Imaging tools such as computed tomography, magnetic resonance angiography, fludeoxyglucose positron emission tomography-computed tomography and more recently contrast-enhanced ultrasonography are frequently used in the diagnosis and to assess vascular inflammation.(1)

Accumulating evidence has shown that biological agents such as anti-tumor necrosis factor agents, tocilizumab and rituximab could be used effectively in refractory cases.(1) Loricera et al. have shown that tocilizumab appears to be effective in the management of patients with TA, particularly in patients refractory to corticosteroids and/or conventional immunosuppressive drugs.(10)

### Case presentation 1

A 53-year-old Asian man, developed sudden onset severe abdominal pain. He had noticed episodes of mild abdominal pain in the preceding month, along with constitutional features. He also complained of dizziness. The pain was not postprandial. His bowel habits were normal. He did not give a history of back pain.

Examination did not reveal any murmurs or bruits. The abdomen was nontender. There were no

features suggestive of systemic lupus erythematosus. Initially, he was treated with intravenous pantoprazole on the assumption that the pain was due to gastritis, to which there was no response. The ECG t and troponin T levels were both normal. A CT aortic angiogram was performed on the same day that he developed disabling pain. There was enhancing soft tissue thickening of a long sequence of the coeliac axis extending to common hepatic and splenic arteries causing external compression with luminal narrowing. There was uniform thickening of the aortic arch and the wall of the descending aorta. The right renal artery demonstrated mild thickening at the origin (figure 1A).

An MRI scan performed on the next day demonstrated inflammatory changes in the retroperitoneum at the origin of the coeliac axis. MRA of the brain demonstrated subtle wall thickening of the M2 segment of the left middle cerebral artery. His ESR was 82 mm/1<sup>st</sup> hour.

The patient was commenced on methotrexate and administered 1000 mg of intravenous methylprednisolone for three consecutive days. After 3 days, this 55 kg patient was commenced on 1 mg/kg of oral prednisolone and the dose was reduced by 5 mg every week while monitoring disease activity with the ESR. The abdominal pain improved significantly. The CT aortogram was repeated 8 weeks later, and showed almost complete resolution of arterial wall thickening of the coeliac axis and the proximal hepatic artery. Mild residual thickening of the splenic arterial wall was seen (figure 1B). The ESR had dropped to 14 mm/1<sup>st</sup> hour. The patient was completely asymptomatic by this time.

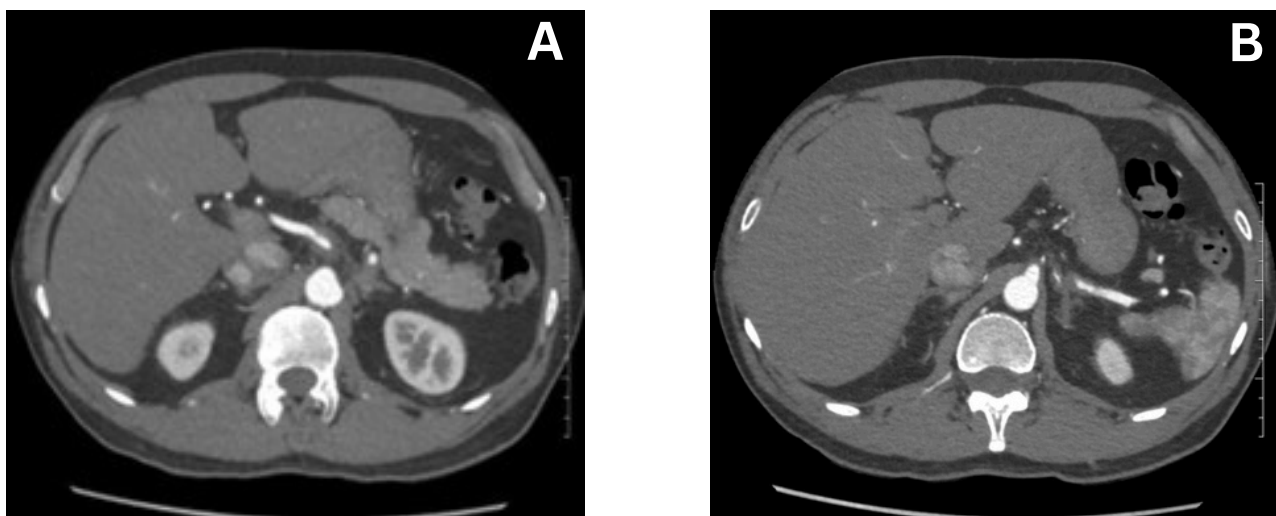


Figure 1 - CT aortogram; Before treatment A, After treatment B

## Case presentation 2

A 48-year-old Asian woman presented with pain down the left arm. Her history dated back to 14 months, when she had presented with severe pain down the left arm with dysaesthesia. The patient was investigated for ischaemic heart disease. In two weeks she developed excruciating pain in the 4th finger of left hand which changed colour. There had been no evidence of vasculopathy or trauma. The patient was a non-smoker. The left radial pulse was absent, and the brachial pulse was of low volume. The CT angiography of the thoracic aorta and left upper limb revealed circumferential wall thickening of the origin of the left subclavian artery, with significant luminal narrowing of approximately 50% (figure 2).

The patient was commenced on methotrexate and 0.5 mg/kg of oral methylprednisolone about three weeks after the onset of pain. Despite increasing doses of methotrexate, there was no improvement of the symptoms. The patient decided to travel to India for medical treatment. In India, she was treated with two doses of tocilizumab. There was some improvement in the pain. The patient was asked to repeat a CT aortogram. Due to financial constraints, the next angiography was performed seven months later. This scan was almost identical to the first scan, but the luminal narrowing had increased up to 60%. In addition, mild eccentric atheromatous lesions were seen in the infra-renal abdominal aorta, causing no significant luminal narrowing. The patient was developing worsening upper limb pain. Due to the unavailability of tocilizumab and the recurrence of symptoms she was commenced on mycophenolate

mofetil. Six weeks following mycophenolate mofetil therapy she improved clinically. Two months later the patient started developing the same symptoms again. She was commenced on tofacitinib 5 mg twice daily to which she has responded remarkably up to now.

## Discussion

According to the 2022 American College of rheumatology/EULAR classification criteria for Takayasu arteritis(11) both patients fulfil the criteria for diagnosis of TA. When referring to the 2021 American College of rheumatology/vasculitis foundation guideline for the management of giant cell arteritis and Takayasu arteritis(12) both patients presented with features of both active and severe disease.

When considering the first patient, although involvement of the descending and abdominal aorta is more commonly seen in Asians, associated retroperitoneal fibrosis makes it a rare presentation of TA. Only five such cases have been reported in the literature so far.(13) Abdominal pain is rarely described as a clinical manifestation of Takayasu arteritis, although abdominal vascular involvement is common.(14)

The second patient had ischaemia of a digit which is rarely reported, which appeared after 2 weeks of the initial presentation. Ischaemic heart disease (IHD) was considered initially in this patient. While considering ischaemic heart disease in a patient with pain down the left arm is of paramount importance, other diagnoses also should be entertained,

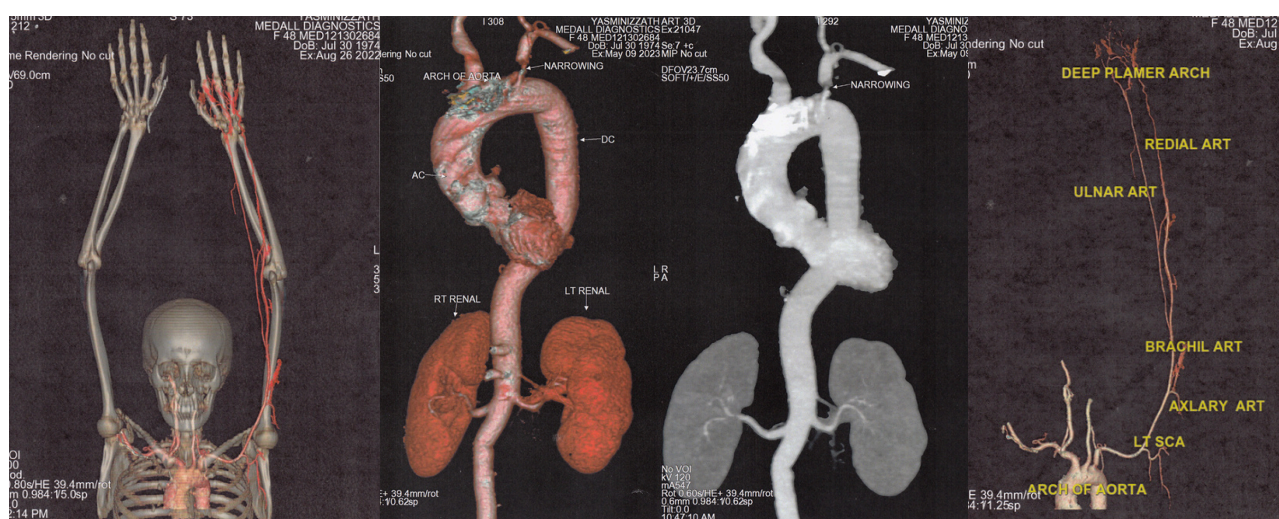


Figure 2 - Images depicting narrowing at the origin of the left subclavian artery

especially when the investigations supportive of IHD are negative and the symptoms are prolonged. This case reiterates this aspect.

Even though TA is 8-9 times commoner in the female(15) and the subclavian and innominate arteries are the most common sites of stenosis(4), there was a delay of over 3 weeks in commencing immunosuppression. Contrastingly, the patient discussed in the 1st case was fortunate to have the CT aortic angiogram conducted on the same day and have treatment commenced.

The patient in case number one responded almost completely to methotrexate and IV pulse methylprednisolone and subsequent high-dose oral steroids, in eight weeks. There is no evidence that IV pulse glucocorticoids are more effective than high-dose oral glucocorticoids.(12) IV pulse glucocorticoids may be considered for patients with life- or organ-threatening disease, as in patient 01 where there was impending bowel ischaemia.(12) The second patient commenced on treatment three weeks after the onset of symptoms, and was treated with high dose oral steroids and methotrexate initially. The response was poor.

The guidelines recommend the use of a non glucocorticoid immunosuppressive agent such as methotrexate plus glucocorticoids over glucocorticoids alone. Tocilizumab is not recommended as initial therapy. The guidelines recommend tapering off glucocorticoids in TA patients who achieved remission while receiving high-dose glucocorticoids for  $\geq 6-12$  months, for remission maintenance.(1) Patient 01 easily achieved remission in eight weeks, and was maintained on 5 mg of prednisolone which has now been taken off.

Patient 2 who had not achieved remission even at 14 months was continued on low-dose steroids. She was commenced on bisphosphonates to prevent glucocorticoid-induced osteoporosis (GOIP).(16) She was treated with two doses of tocilizumab, to which there was no improvement. Adding a TNF alpha inhibitor is better than tocilizumab at this point.(12) Due to the unavailability of biologics the patient was commenced on mycophenolate mofetil to which she clinically responded initially only to present with recurrent symptoms in eight weeks. She was commenced on tofacitinib 5 mg twice daily to which she responded.(17) This patient's treatment history depicts a refractory case of TA.

## Conclusion

There is no literature available on the treatment delay and how it affects the response to treatment in the TA patient. Nonetheless the comparison of these two case reports calls for greater clinical suspicion in considering TA in a patient with ischaemic symptoms of an arterial territory.

## Declarations

### Conflicts of interest

The authors declare that they have no conflicts of interest

### Funding

None

### Author details

<sup>1</sup>Senior Lecturer in Pharmacology, University of Kelaniya and Specialist in Rheumatology and Rehabilitation

<sup>2</sup>Consultant in Rheumatology and Rehabilitation, Ragama Rehabilitation Hospital

## References

- 1.Seyahi E. Takayasu arteritis: an update. *Curr Opin Rheumatol.* 2017 Jan;29(1):51-56. doi: 10.1097/BOR.0000000000000343.
- 2.Fukuda Y, Shirai K, Takamiya Y, et al. Isolated pulmonary arterial stenosis caused by Takayasu's arteritis in an elderly male. *J Cardiol.* 2008; 51:196-200. doi: 10.1016/j.jjcc.2007.12.003.
- 3.Zhu G, He F, Gu Y, et al. Angioplasty for pediatric renovascular hypertension: a 13-year experience. *Diagn Interv Radiol.* 2014; 20:285-92. DOI 10.5152/dir.2014.13208.
- 4.Wang H, Lai B, Wu X, et al. Late diagnosis of Takayasu's arteritis with repeated attacks of heart failure and uncontrolled hypertension due to abdominal aortic thrombosis: case report and review of the literature. *Blood Press.* 2015;24(6):333-9. doi: 10.3109/08037051.2015.1049423.
- 5.Serra R, Butrico L, Fugetto F, et al. Updates in Pathophysiology, Diagnosis and Management of Takayasu Arteritis. *Ann Vasc Surg.* 2016 Aug; 35:210-25. doi: 10.1016/j.avsg.2016.02.011.
- 6.Arnaud L, Haroche J, Mathian A, et al. Pathogenesis of Takayasu's arteritis: a 2011 update. *Autoimmun Rev.* 2011 Nov;11(1):61-7. doi: 10.1016/j.autrev.2011.08.001.
- 7.Schäfer VS, Brossart P, Warrington KJ, et al. The role of autoimmunity and autoinflammation in giant cell arteritis: A systematic literature review.
- 8.Eshed I, Druyan A, Stern M, et al. The prevalence of sacroiliitis on abdominal MRI examinations of patients with Takayasu arteritis. *Acta Radiol.* 2022 Mar;63(3):387-392. doi: 10.1177/0284185121996270.
- 9.Zhu FP, Luo S, Wang ZJ, et al. Takayasu arteritis: imaging spectrum at multidetector CT angiography. *Br J Radiol.* 2012 Dec;85(1020): e1282-92. doi: 10.1259/bjr/25536451.

10. Loricera J, Blanco R, Hernández JL, et al. Tocilizumab in patients with Takayasu arteritis: a retrospective study and literature review. *Clin Exp Rheumatol*. 2016 May-Jun;34(3 Suppl 97): S44-53.
11. Grayson PC, Ponte C, Suppiah R, et al. DCVAS Study Group. 2022 American College of Rheumatology/EULAR classification criteria for Takayasu arteritis. *Ann Rheum Dis*. 2022 Dec;81(12):1654-1660. doi: 10.1136/ard-2022-223482.
12. Maz M, Chung SA, Abril A, et al. 2021 American College of Rheumatology/Vasculitis Foundation Guideline for the Management of Giant Cell Arteritis and Takayasu Arteritis. *Arthritis Rheumatol*. 2021 Aug;73(8):1349-1365. doi: 10.1002/art.41774.
13. Jghaimi F, Kabbaj A, Essaadouni L. Maladie de Takayasu et fibrose rétro-péritonéale: une nouvelle observation [Takayasu's arteritis and retroperitoneal fibrosis: a case report]. *Rev Med Interne*. 2010 Mar;31(3): e1-3. French. doi: 10.1016/j.revmed.2009.01.001.
14. Sasae Y, Morita Y, Sakuta T, et al. Abdominal pain as the initial presentation of Takayasu arteritis. *Mod Rheumatol*. 2008;18(5):496-8. doi: 10.1007/s10165-008-0075-7.
15. Yousefghahari B, Ghorbani H, Hashemougli A. Takayasu arteritis in a young female. *Caspian J Intern Med*. 2011 Summer;2(3):283-5.
16. Hayes KN, Baschant U, Hauser B, et al. When to Start and Stop Bone-Protecting Medication for Preventing Glucocorticoid-Induced Osteoporosis. *Front Endocrinol (Lausanne)*. 2021 Dec 15;12:782118. doi: 10.3389/fendo.2021.782118. Erratum in: *Front Endocrinol (Lausanne)*. 2022 Mar 14;13:877512.
17. Mv P, Maikap D, Padhan P. Successful Use of Tofacitinib in Refractory Takayasu Arteritis: A Case Series. *Mediterr J Rheumatol*. 2023 Jul 31;34(3):356-362. doi: 10.31138/mjr.230929.su.

**Received:** 13 Dec 2023**Accepted:** 31 May 2024